

# Another Restorative Option for the Dentally Disastrous

by Ifran Atcha, DDS, with Luke Kahng, CDT



This 45-year-old female patient presented with a history of missing front teeth due to trauma 15 years ago. Because of the missing anterior teeth, her gum tissue color was checked before the work began so as to have a valid description for the technician when he began the work on her case (Fig. 1). She was not happy with her ill-fitting partial which had a broken clasp assembly. The teeth in the anterior were very unaesthetic and there was no retention to the partial denture on the abutment teeth. The patient wore the partial constantly since she did not want

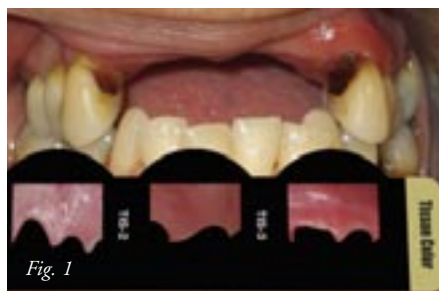

Fig. 1

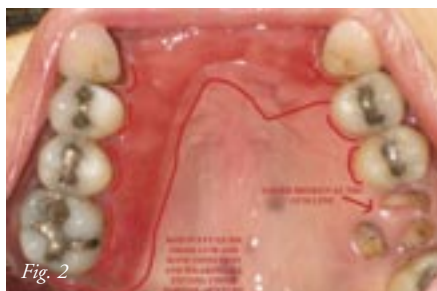

Fig. 2

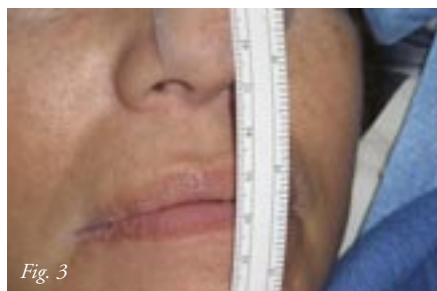

Fig. 3

her husband to see her without front teeth. The occlusion was completely off in the partial denture, leaving her with a red, inflamed palate and gums due to chronic irritation. In addition, it did not provide any lip support. Smiling was not something she was inclined to do with this appliance in place.

Existing upper dentition was hopeless due to periodontal disease and caries (Fig. 2). Vertical dimension was collapsed and the smile line, which should connect the biting edges of the top teeth, was off (Fig. 3). Smiles should follow the curve of the lower lip. In contrast, a flat smile line indicates aged worn teeth, while a curved smile line suggests youth.

X-Rays/CBCT showed alveolar atrophy in the premaxilla area due to loss of dentition and decreased function. Existing teeth were hopeless with poor prognosis due to periodontal disease and caries. Pre-operatively, her tissue condition was very poor and inflamed as well, since she never removed the partial denture.

The developed treatment plan was to extract all of the teeth in the maxillary dental arch and have a fixed nonremovable screw-retained hybrid placed at the time of surgery. The final prosthesis would follow in six months time. The patient had no allergies, was considered ASA Class I, with excellent medical history and no prescribed medications. After discussion, the treatment plan was accepted in its entirety.

### Case Study

The patient was given full intravenous anesthesia for comfort and pain management before the extractions. Local anesthesia was used by means of V2 and infrorbital blocks with a total of three carpules of septocaine (4 percent) with 1:200,000 epi and three carpules of Bupivacaine (0.5 percent) with 1:200,000 epi. The full intravenous anesthesia was accomplished by placing a 20G intravenous catheter in the dorsum of the right hand. Sedative agents, narcotics and hypnotic agents such as Versed, Fentanyl and Propofol were used for induction and maintenance of anesthesia. The doses were titrated based on patient's medical history and body weight. Patient was ASA Class I and has complete retrograde amnesia of the event.

After the surgical procedure (Fig. 4), in which five Nobel Speedy Groovy external connection implants were placed (Fig. 5), the clinician verified placement via CBCT to check if the implants were placed in the triangle of bone (Fig. 6). Multi-unit straight, 17-degree and 30-degree abutments were placed to the fixtures at the time of the surgery. The provisional appliance, a screw-retained full upper hybrid denture, made in advance of the surgery but completed chairside, was loaded on five implants. The temporary hybrid denture was placed and present in the patient's mouth for

*Fig. 1: Before work on her case began, the patient's tissue color was checked using the Chair Side Shade Selection Guide.*

*Fig. 2: The patient's gums were red and puffy, with many areas of caries and periodontal disease from wearing an ill-fitting partial denture for many years.*

*Fig. 3: Vertical dimension was checked by the clinician chairside.*

*Fig. 4: All maxillary teeth in the dental arch were extracted.*

*Fig. 5: After extractions, five Nobel Speedy Groovy external connection implants were placed.*

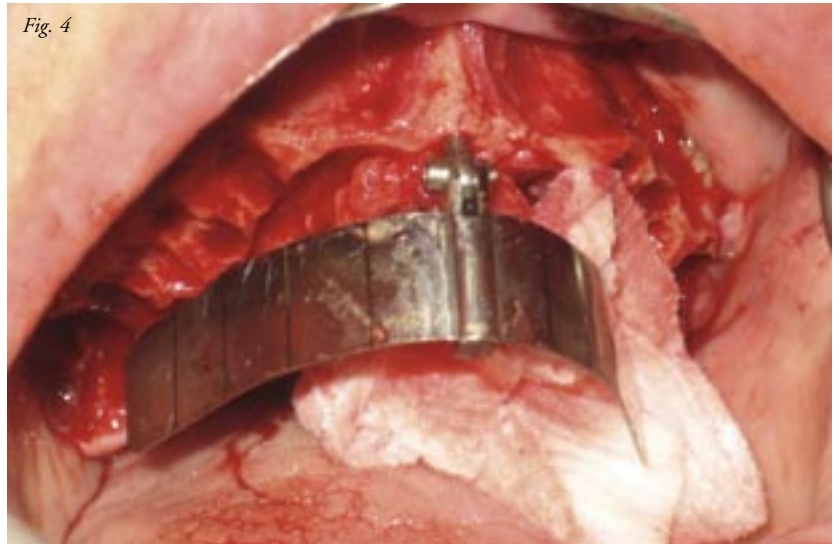

Fig. 4

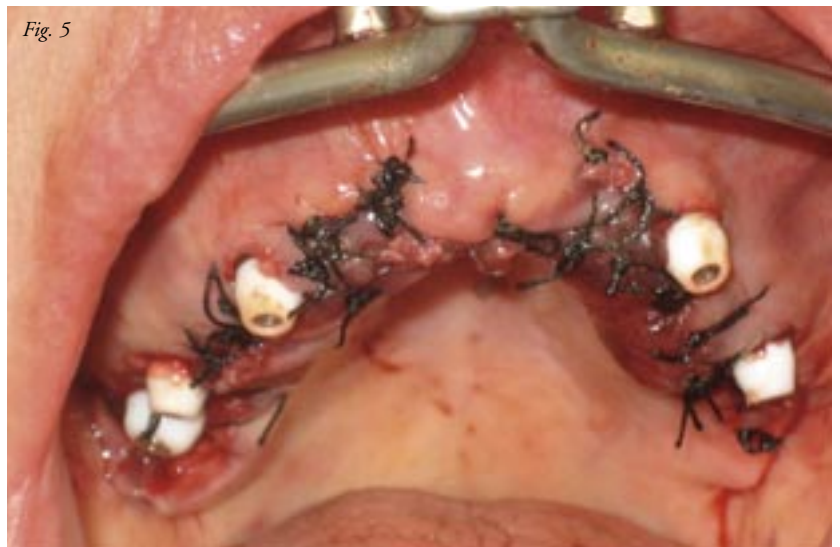

Fig. 5

continued on page 70

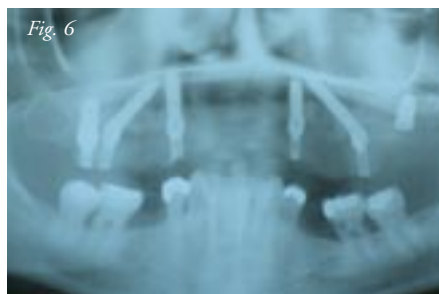

Fig. 6

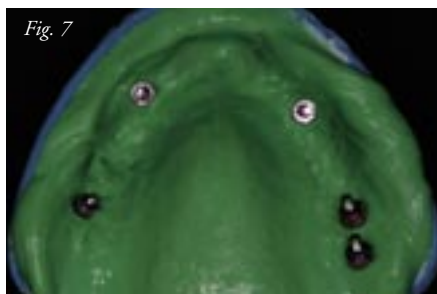


Fig. 7

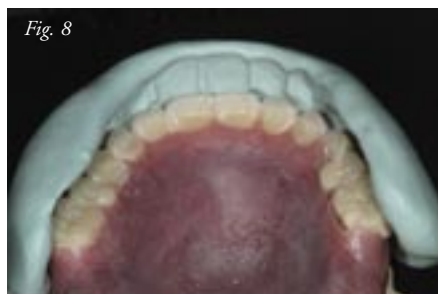

Fig. 8



Fig. 9




Fig. 10



Fig. 11

Fig. 6: The clinician verified placement via CBCT to check to see if the implants were placed in the triangle of bone.

Fig. 7: Three months later, an open tray polyether impression was taken and sent to the lab for processing.

Fig. 8: The putty matrix was placed over the top of the temporary denture to verify proper fit and frame design.

Fig. 9: A verification index was placed to give the technician proper size and correct positioning guidance for the indirect composite teeth.

Fig. 10: Using the Nobel Procera CAD/CAM scanner, the dental model, with light-cured Primotec wax-up over the top, was scanned and sent for processing.

Fig. 11: GC Gradia Opaque material was applied to the bar.

Fig. 12: GC Gradia Gum material was used to create tissue color for the final denture.

Fig. 13: The final denture was placed on a mirrored surface for an aesthetic check.

Fig. 14: The finished denture was tried in the patient's mouth.

three months with on-point centric occlusion and only canine rise with total anterior disclusion in protrusive movement to avoid lateral forces on the implants. An occlusal guard was fabricated and given to the patient with instructions for wear in order to prevent a parafunction. Three months later, an open tray polyether impression was taken (Fig. 7) and sent to the lab for processing. The lab analog was then placed in order to make the soft tissue model. From there, the putty matrix was positioned over the top of the temporary denture to verify proper fit and frame design (Fig. 8). Impression copings were removed from the impression and a verification index placed to give the technician proper size and correct positioning guidance for the indirect composite teeth (Fig. 9).

Using Primotec with light cure wax for consistent quality, a wax model of the putty matrix was placed over the model and scanned using the Nobel Procera CAD/CAM scanner (Fig. 10). Once ordered, the bar took approximately two weeks to be completed and sent back to the lab.

After a metal primer was applied to the titanium bar, GC Gradia Opaque material was layered over the top (Fig. 11). For proper tissue color, GC Gradia Gum (G-23) material was used in the build-up process (Fig. 12). The completed denture, alongside the screws, was checked against a mirrored surface (Fig. 13) and tried in the mouth for a retracted size and fit check (Fig. 14) before final placement (Fig. 15).

The patient's claims her treatment exceeded her expectations and offers her truly brilliant smile for the camera (Fig. 16).

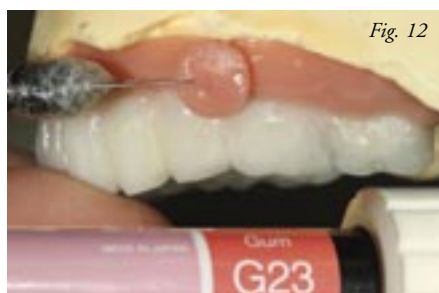

Fig. 12

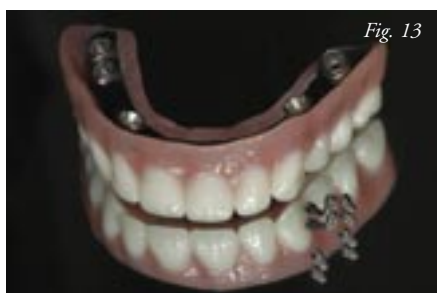

Fig. 13

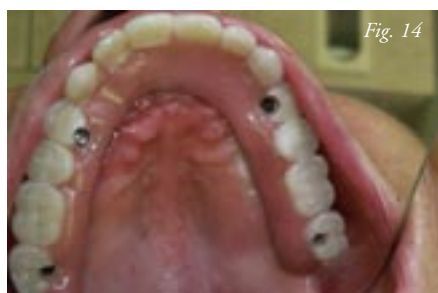

Fig. 14

## Conclusion

This female patient was tired of having broken down teeth and an ill-fitting partial that she had been wearing for more than a decade. Her natural teeth that were attaching to the partial were broken down, had caries and periodontal breakdown and were hopeless. She was facing the probability of needing a full denture in the immediate future and wanted a fixed option with dental implants. The doctor and patient discussed all possibilities from fixed implant teeth to a removable full denture. Together they decided on this choice.

This proven technique is a vast enhancement over a denture for the many patients who have suffered the nutritional, emotional and social embarrassment of missing teeth for years. When one considers the financial impact of placing four to six implants with the “All-on-4 Teeth-in-a-Day” method as opposed to eight, 10, 12, or 14 implants, it is a money saving procedure as well. No bone graft is needed for these solutions, and patients can have immediate teeth on the day of the surgery versus a two-stage surgery dictated by a more traditional approach and having to wear a temporary denture.

This case helps to see just what a difference a beautiful smile can make for an individual. Eating out has become a social and enjoyable event for her. Her happiness and enriched lifestyle have affected her friends and family as well. ■

### Special Acknowledgement:

Steve Stevens, Lake Side Dental, Mokena, Illinois

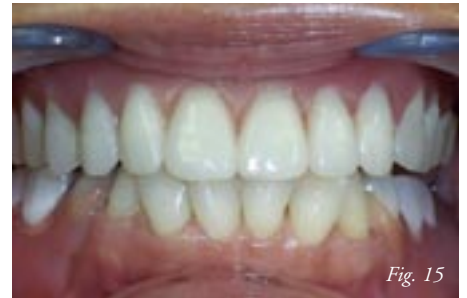

Fig. 15

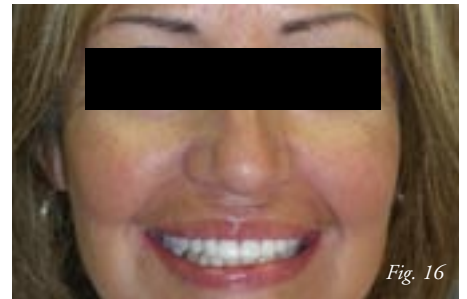

Fig. 16

Fig. 15: Retracted view of the denture in the patient's mouth.

Fig. 16: Final, smile view

## Author's Bio

**Dr. Irfan (Ivan) Atcha** graduated from the University Of Illinois College Of Dentistry in 1996. Since then he has taken extensive postgraduate advanced education classes in implant dentistry (surgical and prosthetic component) all over the world, from world-class clinicians such as Dr. Carl Misch, Dr. Arun Garg, Dr. Peter Moy, Dr. Palo Malo, Yvan Fortin and Dr. Thomas Belshi. His practice is dedicated to help the dentally disastrous, orally handicapped and complex full-mouth implant cases. He has presented lectures and table clinics on numerous occasions locally and at international implant meetings. He is a diplomat of the International Congress of Oral Implantologists and a Diplomat of the American Dental Implant Association. He is also on the board of directors of the American Dental Implant Association. His practice is limited to treating complex care implant patients with the “All-on-4” technique – immediate loading and graft-less solutions with a conventional and guided approach utilizing the NobleGuide concept. Dr. Atcha also has advanced training to help patients who experience extreme fear associated with total intravenous anesthesia. For more information, please visit [www.chicagonodentures.com](http://www.chicagonodentures.com) and contact [teethforyou@gmail.com](mailto:teethforyou@gmail.com) or [dratcha@sbcglobal.net](mailto:dratcha@sbcglobal.net).



**Luke S. Kahng, CDT** is the owner of LSK121 Oral Prosthetics, a dental laboratory in Naperville, Illinois. In addition to being a board member for several dental publications, he has also published more than 60 articles with major dental journals. He is the author of three books, including *Anatomy from Nature*, with 50 illustrated pages of full contour wax-ups, stone models and porcelain teeth, all recreated using natural teeth as a guide, the *Esthetic Guide Book* featuring 31 patient cases from a single anterior tooth to a full mouth reconstruction and *Smile Selection + CS<sup>3</sup> Clinical Cases*, a complete supplement to the *Chair Side Shade Selection Guide Standard Kit*. He invented the *Chair Side Shade Selection Guide* and the *Simple Enamel and Prep Color Guide*, featuring more than 150 zirconia fabricated restorations based on patient enamel and translucency research, with patent pending, in 2009.

